



# Posterior crossbite in the deciduous dentition period, its relation with sucking habits, irregular orofacial functions, and otolaryngological findings

Stasa Melink,<sup>a</sup> Mojca Velikonja Vagner,<sup>b</sup> Irena Hocevar-Boltezar,<sup>c</sup> and Maja Ovsenik<sup>d</sup>

Ljubljana, Slovenia

**Introduction:** The aim of this study was to assess unilateral posterior crossbite, sucking habits, orofacial functions, and otolaryngological findings in the deciduous dentition. These findings would allow us to establish a preventive program for posterior crossbite, based on interceptive treatment at an early stage of dental development. We would determine the predictive value for posterior crossbite development in correlation with the duration of sucking habits. **Methods:** Data were collected on 30 children (13 boys, 17 girls) with unilateral posterior crossbite (mean age, 5.5 years; range, 3.6-7.2 years) and 30 children (17 boys, 13 girls) without crossbite (mean age, 5.9 years; range, 5.4-6.7 years), randomly selected from a local kindergarten. Information about each subject's nutritive and nonnutritive sucking behaviors was collected through parent interviews and questionnaires. An orthodontist and an otolaryngologist clinically examined all the children. Study models were obtained from all children, and dental arch parameters including arch widths in the canine and second deciduous molar regions were measured directly from the models. The data were then compared between the posterior crossbite and the noncrossbite groups. **Results:** The results indicated correlations between prolonged pacifier sucking habit ( $P = 0.001$ ), short frenulum linguae ( $P < 0.001$ ), smaller maxillary arch width ( $P < 0.001$ ), greater mandibular arch width ( $P < 0.002$ ), and unilateral posterior crossbite. A receiver operating characteristic curve was plotted for the pacifier sucking time. The borderline for the development of posterior crossbite suggested by the receiver operating characteristic curve was 18 months of pacifier sucking duration. The odds ratios between the crossbite and noncrossbite groups were 3.6 (CI = 0.97-13.4) for pacifier habit duration of 18 to 35 months and 21.9 (CI = 3.7-129.4) for pacifier suckers of more than 36 months. No significant correlation between enlarged adenoids and tonsils or impaired nasal breathing and the crossbite was found. **Conclusions:** These results suggest that the duration of a pacifier habit and a short frenulum linguae are associated with posterior crossbite at the age of 4 or 5 years because of the low tongue posture in the mouth. Pediatricians and pedodontists should give precise recommendations for enhancing breast feeding and discontinuing pacifier habits at least until the child is 18 months of age. Further studies are also needed to determine more objectively the etiology of tongue posture, swallowing pattern, and the length of the frenulum linguae in children with posterior crossbite. (Am J Orthod Dentofacial Orthop 2010;138:32-40)

From the Department of Orthodontics, Medical Faculty, University of Ljubljana, Ljubljana, Slovenia.

<sup>a</sup>PhD and Postgraduate student, University of Ljubljana, Faculty of Medicine, Department of Orthodontics, Ljubljana, Slovenia.

<sup>b</sup>Specialist of orthodontics, Dental Polyclinic Kranj, Slovenia.

<sup>c</sup>Professor, otolaryngology specialist, University of Ljubljana, Faculty of Medicine, Department of Otorhinolaryngology and Head and Neck Surgery, Ljubljana, Slovenia.

<sup>d</sup>Assistant professor.

The authors report no commercial, proprietary, or financial interest in the products or companies described in this article.

Reprint requests to: Maja Ovsenik, University of Ljubljana, Medical Faculty, Department of Orthodontics, Vrazov trg 2, 1000 Ljubljana, Slovenia; e-mail, [maja.ovsenik@dom.si](mailto:maja.ovsenik@dom.si).

Submitted, March 2008; revised and accepted, September 2008.

0889-5406/\$36.00

Copyright © 2010 by the American Association of Orthodontists.

doi:10.1016/j.ajodo.2008.09.029

**T**oday's emphasis on preventive orthodontic care necessitates rational planning of orthodontic preventive measures among children even in an early stage of dental development.<sup>1</sup> Posterior crossbite is the most prevalent malocclusion in the deciduous dentitions of white children.<sup>2</sup> Without early treatment, it can result in facial asymmetry and temporomandibular disorders in adulthood.<sup>2</sup> Furthermore, the muscular hyperactivity on the crossbite side might have an unfavorable influence on craniofacial growth that can lead to craniofacial asymmetry<sup>2,3</sup> or temporomandibular joint (TMJ) dysfunction and deviation from normal facial esthetics.<sup>4,5</sup>

The functional matrix theory of growth and development by Moss<sup>6</sup> presumes that growth of the face occurs

as a response to functional needs and neurotrophic influences, and is mediated by the soft tissues in which the jaws are embedded. In this conceptual view, the soft tissues grow, and both bone and cartilage react.<sup>6</sup> The conclusion, based on Moss's theory, is that the correct functions of the orofacial complex—breathing, swallowing, and chewing—have a major influence on the growth and correct development of face, jaws, and dentition.

In addition to heredity, other factors involved in the etiology of posterior crossbite are nonnutritive sucking habits and impaired nasal breathing caused by, for example, enlarged tonsils and adenoids.<sup>7</sup> In a review of the literature by Allen et al,<sup>8</sup> the following potential etiologic factors for posterior crossbite were given: prolonged retention or premature loss of deciduous teeth, crowding, palatal cleft, genetic control, arch deficiencies, abnormalities in tooth anatomy or eruption sequence, oral digit habits, oral respiration during critical growth periods, and malfunctioning TMJs. Many authors found that pacifier sucking is an important etiologic factor involved in the formation of a posterior crossbite.<sup>2,8-14</sup>

Bottle feeding, even among breast-fed children, interfered negatively with orofacial development. Lip competence closure, nasal breathing, resting tongue position in the maxillary arch, and normal maxilla were observed statistically significantly more often in children who used only a cup to drink.<sup>15</sup>

Open-mouth posture, as a habit or as a result of adeno-tonsillar enlargement or prolonged inflammation of the nasal mucosa associated with allergies or chronic infections, inhibits transverse maxillary growth and leads to a significant increase in the prevalence of posterior crossbite.<sup>16,17</sup> It is also connected with posterior head posture and facies adenoidea.<sup>16</sup> It seems that, in children with posterior crossbite and those who breathe through their mouth, excessive vertical dimension is associated with deficient transverse dimension; nevertheless, the true relationship between mouth breathing and posterior crossbite is still in question.<sup>8</sup> Lip incompetence plays an important role in the growth and development of the craniofacial complex,<sup>18</sup> although the open-mouth posture does not reflect the mode of breathing.<sup>19</sup>

Children with enlarged tonsils had significantly narrower maxillary arches and a higher prevalence of posterior crossbite; crossbite was also correlated with functional disorders such as open-mouth posture, mouth breathing during sleep, snoring, guttural speech, and dysphagia.<sup>20</sup> Children with enlarged tonsils were found to have a more anterior and inferior position of the tongue and a more inferior position of the hyoid bone than those without enlarged tonsils.<sup>20</sup>

Swallowing pattern progresses from an infantile form, which can persist until 4 years of age, to a mature form. If this does not happen because of obstacles in the mouth that prevent the normal position of the tongue (dummy, finger), the tongue must take a lower position in the anterior part of the mouth. Infantile swallowing pattern is considered a dysfunction because of its association with certain malocclusions.<sup>21</sup>

The development of an occlusion must be considered a result of the interactions between genetically determined developmental factors and several external and internal environmental factors, including orofacial functions.<sup>22,23</sup> Whereas a close relationship between form and function is recognized by many authors, the degree of interplay is still a matter of conjecture. There has been no report in the literature on interdisciplinary clinical examinations of orofacial functions in the primary dentition period by an orthodontist and otolaryngologist.

Therefore, our aim in this study was to find the association between posterior crossbite, sucking habits, orofacial functions, and otolaryngologic findings in the deciduous dentition period to establish an early preventive program for posterior crossbite at an early stage of dental development.

## MATERIAL AND METHODS

From the files of the Department of Pedodontics, Dental Policlinic, Kranj, Slovenia, 30 children with posterior crossbite (13 boys, 17 girls; mean age, 5.5 years; range, 3.6-7.2 years) and 30 children without crossbite (17 boys, 13 girls; mean age, 5.9 years; range, 5.4-6.7 years) were randomly selected from the local kindergarten and invited to participate in this study. The research was approved by the Ethics Committee, University of Ljubljana, Medical Faculty, Ljubljana, Slovenia, and the parents were asked to give informed consent for their children to participate in the study.

Information about a subject's nutritive and nonnutritive sucking behaviors was recorded in the parents' interview (Appendix). Information regarding breast and bottle feeding, pacifier sucking, and allergies was registered in the questionnaire and further discussed by the first author (S.M.).

The durations of breast-feeding and pacifier sucking were categorized by the method described by Warren and Bishara.<sup>13</sup> The duration of breast-feeding was classified into 4 categories: no breast-feeding, breast-feeding less than 6 months, breast-feeding from 6 to 12 months, and breast-feeding more than 12 months. The duration of pacifier sucking was categorized in 4 categories: the habit ceased before 12 months of age, the

habit continued at 12 months but ceased by 24 months, the habit continued at 24 months but ceased by 36 months, and the habit continued at 36 months, but ceased by 48 months.

During the clinical examinations, performed by an experienced orthodontist (M.O.) and an otolaryngologist (I.H.B.), the children's breathing, swallowing, and intraoral status were registered. The mode of breathing was determined with an instrument (Breathing Detector, MKS Elektronski sistemi, Ljubljana, Slovenia) that registers the airflow temperature through the mouth, or nose in subjects with incompetent lip seal, thus distinguishing mouth breathing from incompetent lip seal. Each child was observed in a relaxed position, and incompetent lip closure was noted (Fig 1). If this was not the case, the child's mode of breathing was registered with a special airflow device that registers the difference in the temperature of the airflow through the mouth, or the nose in those with incompetent lip seal. In open-mouth posture, the breathing detector was placed in front of the mouth, and the light sign or the light signal on the device confirmed that the airflow was coming through the mouth, thus determining improper breathing (Fig 1).

To assess the swallowing pattern, we used the method suggested by Melsen et al.<sup>22</sup> This was carried out while the child was swallowing saliva or small amounts of water. First, the mandibular movements and the perioral muscle contractions were observed during swallowing. Then, the examiners palpated the temporalis and masseter muscles while the child produced an unconscious swallow, since this can deviate from a swallow on command. Normal swallowing pattern was characterized by tooth contact and activity of the masseter muscles. If muscle contraction was not registered, an atypical swallowing pattern was recorded. Each child swallowed for 3 times, and the consensus opinion about swallowing pattern was accepted.

During the intraoral examination, posterior crossbite, midline deviation, and transverse buccal relationships were recorded, and alginate impressions of the maxillary and mandibular arches were obtained for both groups of children.

The otolaryngologist's clinical examination was performed while the child was sitting on a chair in a relaxed position. The otolaryngologist examined the tympanic membrane (normal or retracted), nasal mucosa (normal or edematous), possible deviation of the nasal septum, sizes of tonsils and adenoids (small, the tonsils were covered with the arcus palatoglossus; medium, the tonsils were just above the arcus palatoglossus; large, the tonsils were narrowing the isthmus faucium), and objective nasal breathing (possible, obstructed). With

the children in a relaxed position we also noted whether the lips were competent. If this was not the case, the child's breathing was determined with the instrument that registers the difference in airflow temperature through the mouth, or nose in subjects with incompetent lip seal, thus distinguishing mouth breathing from incompetent lip seal (Fig 1). The tongue position (normal or on the mouth floor), length of the frenulum linguae (normal, clinically assessed with lifting the tongue upward to contact the maxillary central incisors; short, could not contact the maxillary central incisors and was obviously short [Fig 2]), motor skills of the tongue (mobility of the tongue: normal or slow) and lips (assessed during speech: in resting position: closed, slightly open, or incompetent), activity of the mentalis muscles, and lip competence (in relaxed closed mouth position: normal, no muscle activity; incompetent, contraction of mentalis muscle observed), and length of the upper lip (normal, short) were also assessed.

To evaluate the dental arches, alginate impressions were poured in hard blue stone, with the casts subsequently trimmed and articulated.

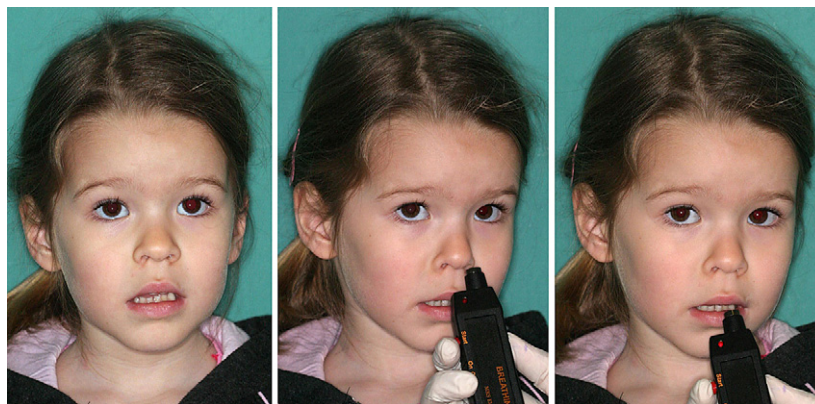
The study casts were analyzed by 1 examiner (S.M.). The relationships of the deciduous canines and second molars, anterior and posterior crossbites, and midline deviations were recorded. Measurements were obtained directly from the casts in millimeters, with calipers accurate to 0.05 mm (Mitutoyo, Tokyo, Japan). The following dental arch parameters were measured: intercanine arch widths from cusp to cusp in the both jaws, intermolar arch widths between the mesiopalatal cusps of the second deciduous molars in the maxilla, and between the central fossae of the second deciduous molars in the mandible (Fig 3), as described by Thilander and Lennartsson.<sup>3</sup>

### Statistical analysis

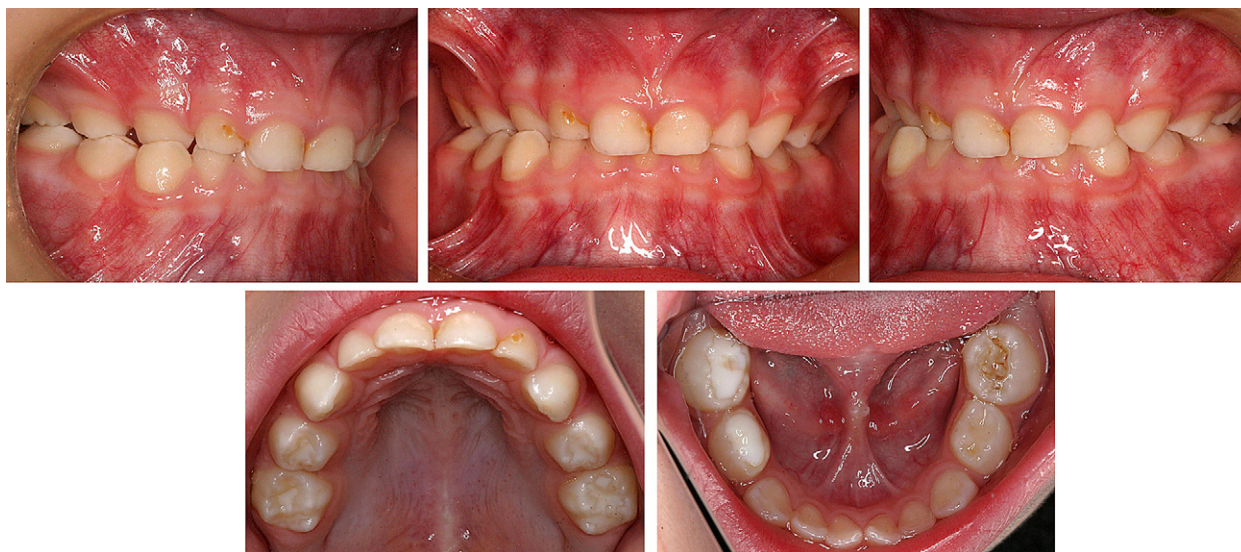Data from the questionnaires, otolaryngologic examinations, and dental arch examinations were analyzed with the SPSS for Windows statistical program (version 15.0, SPSS, Chicago, Ill). The data from the crossbite and noncrossbite groups of children were compared regarding various parameters with univariate analysis of variance (ANOVA), independent samples *t* test, and Mann-Whitney test. The chi-square test was used to compare categorical (attributive) variables between the 2 groups. The Spearman correlation coefficient was used to confirm the relationship between pacifier sucking times and dental arch widths. Statistical significance was predetermined at  $P < 0.05$ .

Receiver operating characteristic (ROC) curve was used to evaluate the influence of pacifier sucking time





**Fig 1.** The breathing apparatus measures airflow. Airflow from the nasal cavity in an open mouth posture (*right*). When the airflow goes through the oral vestibule (*left*), an audible signal or a light is produced.



**Fig 2.** Right, central, and left occlusion, and narrow arches with a short, hypertrophic frenulum linguae in a unilateral crossbite patient.

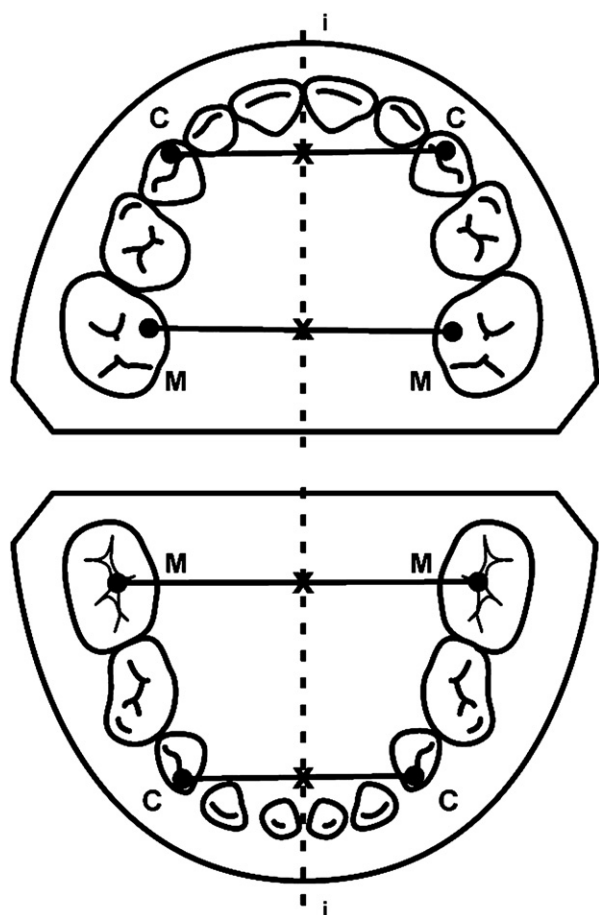
in months on the development of posterior crossbite, as determined by the area under the curve.

## RESULTS

Comparisons of various parameters from the questionnaire regarding nutritive and nonnutritive sucking behaviors between the posterior crossbite and the noncrossbite groups of children showed no statistically significant differences for the durations of breastfeeding and bottle feeding (Table I). However, a statistically significant difference was found between the 2 groups in the duration of pacifier habit ( $P = 0.001$ , Table I).

The otolaryngologic findings (Table II) showed no statistically significant differences between the 2 groups regarding the tympanic membrane and nasal mucosa, shape of the nasal septum, nasal patency, sizes of tonsils and adenoids, objective nasal mode of breathing, tongue position, motor skills of tongue and lips, resting position of the lips, activity of the mentalis muscles and lip competence, length of the upper lip, and atypical swallowing pattern.

The only functional sign that was statistically significantly different between the posterior crossbite and the noncrossbite groups was the length of the frenulum linguae (only crossbite patients had a short frenulum linguae;  $P < 0.001$ , Table II).



**Fig 3.** Measurement of intercanine and intermolar arch widths in both jaws according to Thilander and Lennartsson.<sup>3</sup> C, Canine; M, molar.

**Table I.** Duration in months of sucking habits as reported on questionnaires, compared with Mann-Whitney test and chi-square test for allergy

Sucking habit	Crossbite group Mean (SD)	Control group Mean (SD)	P value
Breast-feeding	6.65 (5.29)	8.96 (6.30)	0.162
Bottle feeding	19.70 (11.91)	14.64 (13.30)	0.092
Pacifier	27.35 (14.04)	16.36 (13.33)	0.001

Regarding dental arch parameters (Table III), in the crossbite group, the maxillary arch was smaller than expected with regard to age, sex, and size of the children in the intercanine ( $P = 0.002$ ) and intermolar ( $P < 0.001$ ) regions, and the mandibular arch was larger than expected with regard to age, sex, and size of the children ( $P = 0.001$  for intercanine and  $P = 0.002$  for intermolar arch widths). No children with the pacifier habit had digit habits.

**Table II.** Clinical examination data for the 2 groups compared with the chi-square test

Parameter	Crossbite group	Noncrossbite group	P value
Presence of an allergy	5 (13.5%)	3 (12.5%)	0.91
Short length of the frenulum linguae	10 (37%)	0 (0%)	<0.001
Retracted tympanic membrane	17 (61%)	16 (59%)	0.10
Edematous nasal mucosa	19 (68%)	20 (74%)	0.62
Deviation of the nasal septum	1 (4%)	4 (16%)	0.13
Large tonsils and adenoids	12 (43%)	13 (48%)	0.70
Impaired nasal breathing	5 (18%)	6 (27%)	0.054
Nasal infection	4 (14%)	7 (32%)	0.054
Mouth floor tongue position	15 (56%)	17 (65%)	0.53
Normal motor skills of tongue	25 (93%)	27 (100%)	0.15
Normal motor skills of lips	26 (96%)	24 (89%)	0.30
Slightly open resting position of the lips (lip competence)	14 (52%)	16 (62%)	0.48
Active mentalis muscles	17 (63%)	12 (46%)	0.22
Short length of the upper lip	20 (74%)	22 (81%)	0.52
Atypical swallowing pattern	6 (22%)	2 (8%)	0.14

**Table III.** Maxillary and mandibular arch dimensions compared with the independent samples *t* test

Measurement		Crossbite group Mean (SD)	Noncrossbite group Mean (SD)	P value*
Maxillary arch widths (mm)	Intercanine	26.69 (2.08)	29.14 (1.79)	0.002
	Intermolar	31.73 (2.27)	34.62 (1.88)	<0.001
Mandibular arch widths (mm)	Intercanine	23.75 (1.36)	23.26 (1.43)	0.001
	Intermolar	34.51 (1.90)	34.06 (1.57)	0.002

\*Adjusted for age, height, weight, and sex.

It was found also that boys had statistically significantly higher values for intercanine arch width in the maxilla ( $P = 0.048$ ) and intermolar arch widths in the maxillary ( $P < 0.001$ ) and mandibular jaws ( $P = 0.002$ ) than the girls. There were no statistically significant differences among the boys and the girls in age (the boys were on average 124 days older than the girls) and presence of posterior crossbite.

The duration of breast-feeding was not statistically significantly correlated with dental arch widths, but an increasing value of the intercanine arch width in the maxilla with longer duration of breast-feeding was observed (Table IV). As has been previously mentioned, the occurrence of posterior crossbite was statistically significantly greater with longer duration of the pacifier habit in the 4 categories ( $P = 0.001$ ). This correlation was linear ( $P < 0.001$ ). Longer duration of the pacifier habit led also to smaller intermolar arch widths in the maxilla, ( $P = 0.028$ , Table V); this was also confirmed with the 2-tailed Spearman correlation (Table VI; intercanine width: correlation

**Table IV.** Comparison of dental arch widths and breast-feeding duration with ANOVA

Arch width (mm)	No breast-feeding (n = 4)	Less than 6 months (n = 19)	6-12 months (n = 28)	More than 12 months (n = 9)	P value*
Maxillary intercanine	27.09 (1.33)	27.54 (2.65)	27.92 (2.17)	28.11 (2.32)	0.450
Maxillary intermolar	32.75 (2.58)	32.50 (2.75)	33.60 (2.44)	32.93 (2.44)	0.523
Mandibular intercanine	24.04 (0.73)	23.32 (1.55)	23.56 (1.34)	23.58 (1.14)	0.829
Mandibular intermolar	35.11 (1.26)	34.27 (1.40)	34.05 (2.09)	34.78 (1.36)	0.917

Values are mean (SD).

\*Adjusted for age, height, weight, and sex.

**Table V.** Comparison of mean dental arch measurements with duration of pacifier habit with ANOVA

Measurement (mm)	Pacifier habit duration				P value*	
	<12 months (n = 16)	13-24 months (n = 17)	25-36 months (n = 19)	37-48 months (n = 6)		
Maxillary arch widths	Intercanine	28.53 (1.75)	28.03 (2.01)	26.55 (2.53)	28.57 (2.18)	0.64
	Intermolar	34.26 (1.71)	33.45 (2.40)	31.93 (2.74)	32.14 (2.82)	0.028
Mandibular arch widths	Intercanine	23.17 (1.44)	23.97 (1.20)	23.26 (1.37)	24.13 (0.81)	0.100
	Intermolar	34.34 (1.83)	34.13 (1.80)	34.58 (1.60)	34.21 (1.80)	0.226

Values are mean (SD).

\*Adjusted for age, height, weight, and sex.

**Table VI.** Correlation between pacifier habit duration, breastfeeding time, and dental arch widths

Spearman rho	Breast-feeding time	Maxillary arch width (mm)		Mandibular arch width (mm)		
		Intercanine	Intermolar	Intercanine	Intermolar	
Pacifier habit duration	Correlation coefficient	-0.316*	-0.259*	-0.376 <sup>†</sup>	0.151	0.070
	Significance (2-tailed)	0.012	0.049	0.004	0.258	0.600

\*Correlation significant at 0.05 level (2-tailed); <sup>†</sup>Correlation significant at 0.01 level (2-tailed).

coefficient, -0.259,  $P = 0.049$ ; intermolar width, correlation coefficient, -0.376,  $P = 0.004$ ). The 2-tailed Spearman correlation (Table VI) also showed that the time of breast-feeding was in reverse proportion to the duration of pacifier habit; the longer the child was breast-fed, the shorter was the duration of pacifier habit (correlation coefficient, -0.316,  $P = 0.012$ ).

The sensitivities and specificities of pacifier sucking times in months and the resultant ROC curves are shown in Figure 4. The area under the curve, a measure of the usefulness or the prognostic value of pacifier sucking time in months as an etiologic factor for the development of posterior crossbite, was high, 0.74 (95% CI, 0.62-0.85). A perfect prognostic test would be an area under the curve of 1.00.

The odds ratios were 3.6 (CI, 0.97-13.4) for the unilateral crossbite children, who were pacifier suckers from 18 to 35 months compared with the noncrossbite children and 21.9 (CI, 3.7-129.4) for the crossbite pacifier suckers of more than 36 months.

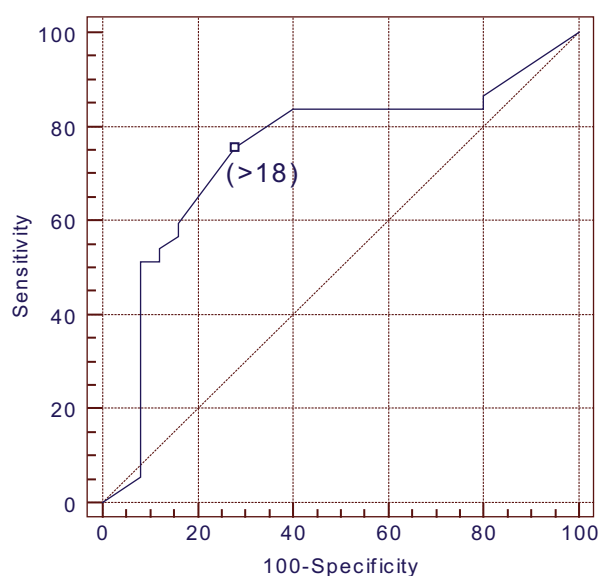
Short frenula linguae were found only in children with posterior crossbite ( $P < 0.001$ ). Short frenula lin-

guae were found also to be statistically significantly correlated with a narrower maxilla in the intercanine and intermolar regions ( $P = 0.01$  and  $P = 0.008$ , respectively; Table VII).

## DISCUSSION

Preventive and early treatment with orthodontics is still the subject of continuous debate and controversy regarding cost-effectiveness, and functional and psychosocial benefits. Early treatment of posterior crossbite is advised to enhance skeletal and dental development and correct habits, improper functions, and malocclusions in their early stages, especially the transverse discrepancies that can cause TMJ problems or facial asymmetry.<sup>1</sup>

The comparisons of the various parameters acquired from the questionnaire regarding nutritive and nonnutritive sucking behaviors between the posterior crossbite and noncrossbite groups of children showed that the positive effects of breast-feeding are difficult to assess because pacifier sucking usually intertwines with



**Fig 4.** ROC curve (the variable is pacifier sucking time in months): pacifier habit duration >18 months, sensitivity 75.7% (CI, 58.8-88.2) and specificity 72.0% (CI, 50.6-87.9).

breast-feeding.<sup>11,13,24</sup> The duration of breast-feeding was not statistically significantly correlated with dental arch widths, but increasing values of intercanine arch width in the maxilla with longer durations of breast-feeding were observed. Breast-feeding seemed to be important in preventing pacifier sucking habits, whereas the correlation analysis confirmed that breast-feeding duration had a reverse relationship with pacifier habit duration. Other researchers confirmed that children with no sucking habits were breast-fed significantly longer (11 months) than those who sucked pacifiers and dummies (5 months).<sup>25</sup>

Early weaning is associated with posterior crossbite because of the lower impact of muscular activity associated with bottle feeding; the consequence is interference with normal development of the alveolar ridges and the hard palate.<sup>5,24</sup> Warren and Bishara<sup>13</sup> could not confirm this statement because they found no significant difference in dental arch parameters and occlusal characteristics among children with minimal nonnutritive sucking habits (<12 months) between those who were breast-fed longer and those with shorter duration of breast-feeding or no breast-feeding. In the study by Lofstrand-Tidestrom et al.<sup>16</sup> of the consequences of bottle feeding in children who were initially breast-fed for at least 6 months, the researchers found that use of bottles interferes negatively with oral and facial development compared with children who used a cup to drink.<sup>16</sup>

A prolonged pacifier habit resulted in significantly more frequent appearance of posterior crossbite.

**Table VII.** Comparison of mean dental arch measurements between children with short and normal frenulum linguae

Measurement (mm)	Length of frenulum linguae		P value*
	Short	Normal	
Mean maxillary arch widths	Inter canine	26.65 (1.50) 28.39 (2.31)	0.010
	Inter molar	31.67 (2.17) 33.43 (2.60)	0.008
Mean mandibular arch widths	Inter canine	24.09 (1.43) 23.60 (1.39)	0.213
	Inter molar	34.66 (1.96) 34.34 (1.60)	0.682

Values are mean (SD).

\*Adjusted for age, height, weight, and sex.

Øgaard et al<sup>11</sup> showed that at least 2 years of nonnutritive sucking habits were necessary to produce a significant effect on the transverse dimension of the maxilla. Warren et al<sup>14</sup> also demonstrated that pacifier habits that persisted beyond 2 or 3 years of age significantly increased the prevalence of posterior crossbite; this was observed also in our study. Questions about the time and intensity of dummy sucking were not asked in our questionnaire, even though the answers would be useful. The area under the ROC curve, a measure of the usefulness or the prognostic value of pacifier sucking time in months as an etiologic factor for development of posterior crossbite, was high: 0.74; this indicates a good prognostic test. From the odds ratios, it can be concluded that children with a pacifier habit duration from 18 to 35 months are 3.6 times (95% CI, 0.97-13.4), and those with a pacifier habit duration of more than 36 months are 21.9 times (95% CI, 3.7-129.4), more susceptible to the development of posterior crossbite than are nonsuckers.

One explanation for the changed equilibrium (form and function balance) in the oral cavity could be that, in children who suck pacifiers, the tongue must take a lower position in the lower and anterior part of the mouth floor; this was diagnosed by the short frenula linguae in our crossbite patients. A short frenulum could be an important factor in the diagnosis of posterior crossbite, most probably due to low tongue posture. Incorrect tongue position on the mouth floor disturbs the dynamic balance between the tongue, cheeks, and lips. There is no formative influence on the oral surfaces of the teeth and alveolar ridges for the maxilla, and thus the activities of lips and cheeks on the buccal surfaces of the maxillary teeth and the alveolar ridge prevail. The consequence of permanent ruin of the normal functional balance is a narrow and short maxilla. Diminished space in the maxilla forces the tongue to lie on the bottom of the oral cavity; this leads to the development of the short frenulum linguae found in all crossbite children.



According to Thilander and Lennartsson,<sup>3</sup> the crossbite side, measured to the midline, was narrower than the noncrossbite side in the maxilla but broader in the mandible. Differences between maxillary and mandibular widths (at the intercanine and intermolar levels) seem to be important for correction or noncorrection, both for untreated and treated children. The narrow crossbite side in the maxilla and the broad crossbite side in the mandible that we found in this study are probably the most important etiologic factors for posterior crossbite development. A possible reason for the broad mandibular arch on the crossbite side might be the irregular tongue posture on the mouth floor, leading to a short frenulum linguae and irregular tongue function; these were found to be significant in the children with posterior crossbite in the deciduous dentition period.<sup>23</sup>

A short frenulum linguae was a significant clinical sign for all children with unilateral crossbite. Therefore, in children with dummy sucking behavior, the length of the frenulum linguae should be determined early in the period of growth and development, because it is probably a result of improper tongue posture and function due to changed dynamics in the oral cavity as a result of functional adaptation to differences in form and function balance.<sup>23</sup>

## CONCLUSIONS

On the basis of our results, the following should be emphasized.

1. To intercept the development of crossbites and functional shifts, parents and pediatricians should assess orofacial functions in young children with a history of prolonged pacifier and bottle feeding habits.
2. Every clinical examination of a child with nonnutritive sucking habits should include assessments of the length of the frenulum linguae and the resulting tongue posture.

## REFERENCES

1. Ovsenik M, Farcnik FM, Verdenik I. Comparison of intra-oral and study cast measurements in the assessment of malocclusion. *Eur J Orthod* 2004;26:273-7.
2. Kuroi J, Berglund L. Longitudinal study and cost-benefit analysis of the effect of early treatment of posterior cross-bites in the primary dentition. *Eur J Orthod* 1992;14:173-9.
3. Thilander B, Lennartsson B. A study of children with unilateral posterior crossbite, treated and untreated, in the deciduous dentition—occlusal and skeletal characteristics of significance in predicting the long-term outcome. *J Orofac Orthop* 2002;63:371-83.
4. Kuroi J. Early treatment of tooth-eruption disturbances. *Am J Orthod Dentofacial Orthop* 2002;121:588-91.
5. Malandris M, Mahoney EK. Aetiology, diagnosis and treatment of posterior cross-bites in the primary dentition. *Int J Paediatr Dent* 2004;14:155-66.
6. Moss ML. The differential roles of periosteal and capsular functional matrices in orofacial growth. *Eur J Orthod* 2007;29:96-101.
7. Petren S, Bondemark L, Soderfeldt B. A systematic review concerning early orthodontic treatment of unilateral posterior crossbite. *Angle Orthod* 2003;73:588-96.
8. Allen D, Rebellato J, Sheats R, Ceron AM. Skeletal and dental contributions to posterior crossbites. *Angle Orthod* 2003;73:515-24.
9. Bishara SE, Warren JJ, Broffitt B, Levy SM. Changes in the prevalence of nonnutritive sucking patterns in the first 8 years of life. *Am J Orthod Dentofacial Orthop* 2006;130:31-6.
10. Keski-Nisula K, Lehto R, Lusa V, Keski-Nisula L, Varrela J. Occurrence of malocclusion and need of orthodontic treatment in early mixed dentition. *Am J Orthod Dentofacial Orthop* 2003;124:631-8.
11. Øgaard B, Larsson E, Lindsten R. The effect of sucking habits, cohort, sex, intercanine arch widths, and breast or bottle feeding on posterior crossbite in Norwegian and Swedish 3-year-old children. *Am J Orthod Dentofacial Orthop* 1994;106:161-6.
12. Stahl F, Grabowski R. Orthodontic findings in the deciduous and early mixed dentition—inferences for a preventive strategy. *J Orofac Orthop* 2003;64:401-16.
13. Warren JJ, Bishara SE. Duration of nutritive and nonnutritive sucking behaviors and their effects on the dental arches in the primary dentition. *Am J Orthod Dentofacial Orthop* 2002;121:347-56.
14. Warren JJ, Bishara SE, Steinbock KL, Yonezu T, Nowak AJ. Effects of oral habits' duration on dental characteristics in the primary dentition. *J Am Dent Assoc* 2001;132:1685-93.
15. Carrascoza KC, Possobon Rde F, Tomita LM, Moraes AB. Consequences of bottle-feeding to the oral facial development of initially breastfed children. *J Pediatr (Rio J)* 2006;82:395-7.
16. Lofstrand-Tidestrom B, Thilander B, Ahlqvist-Rastad J, Jakobsson O, Hultcrantz E. Breathing obstruction in relation to craniofacial and dental arch morphology in 4-year-old children. *Eur J Orthod* 1999;21:323-32.
17. Proffit WR, Fields HW. Contemporary orthodontics. St Louis: Mosby; 2000.
18. Drevensek M, Stefanac-Papic J, Farcnik F. The influence of incompetent lip seal on the growth and development of craniofacial complex. *Coll Antropol* 2005;29:429-34.
19. Hartgerink DV, Vig PS. Lower anterior face height and lip incompetence do not predict nasal airway obstruction. *Angle Orthod* 1989;59:17-23.
20. Behlfelt K, Linder-Aronson S, McWilliam J, Neander P, Laage-Hellman J. Dentition in children with enlarged tonsils compared to control children. *Eur J Orthod* 1989;11:416-29.
21. Peng CL, Jost-Brinkmann PG, Yoshida N, Miethke RR, Lin CT. Differential diagnosis between infantile and mature swallowing with ultrasonography. *Eur J Orthod* 2003;25:451-6.
22. Melsen B, Attina L, Santuari M, Attina A. Relationships between swallowing pattern, mode of respiration, and development of malocclusion. *Angle Orthod* 1987;57:113-20.
23. Ovsenik M. Incorrect orofacial functions until 5 years of age and their association with posterior crossbite. *Am J Orthod Dentofacial Orthop* 2009;136:375-81.
24. Thilander B, Pena L, Infante C, Parada SS, de Mayorga C. Prevalence of malocclusion and orthodontic treatment need in children and adolescents in Bogota, Colombia. An epidemiological study related to different stages of dental development. *Eur J Orthod* 2001;23:153-67.
25. Larsson E. Sucking, chewing, and feeding habits and the development of crossbite: a longitudinal study of girls from birth to 3 years of age. *Angle Orthod* 2001;71:116-9.



