American Journal of Orthodontics
V. 47, 1961

Malfunction of the tongue

Part II. The abnormal swallowing habit: its causes, effects, and results in relation to orthodontic treatment and speech therapy

WALTER J. STRAUB, D.D.S., M.S., F.I.C.D.
San Mateo, Calif.

DURING growth of the mandible certain changes occur in the mandibular plane angle as a result of pressure of the tongue between the teeth during abnormal swallowing over a period of years. The greatest change takes place in the so-

Presented at the biennial meeting of the Pacific Coast Society of Orthodontists, Santa Barbara, California, Feb. 24, 1958; read before the Northern Section of the Pacific Coast Society of Orthodontists, Seattle, Washington, June 3, 1958; the Southern Section of the Pacific Coast Society of Orthodontists, Los Angeles, California, June 5, 1958; the Thirty-fourth Congress of the European Orthodontic Society, Copenhagen, Denmark, July, 1958; the San Mateo County Dental Society, San Mateo, California, Feb. 3, 1959; the Phoenix-Tucson Orthodontists Society, Phoenix, Arizona, Feb. 8, 1959; the Phoenix Central Section of the Dental Society, Phoenix, Arizona, Feb. 9, 1959; the Illi-Wash Study Club of Los Angeles, Beverly Hills, California, Aug. 19, 1959; the University of California, School of Dentistry, Postgraduate Education, San Francisco, California, Oct. 3, 1959 (as an all-day course); the University of California Alumni Association, Jan. 24, 1960; and the Mid-Peninsula Dental Society, Jan. 21, 1959. This paper has also been presented before the Sacramento Dental Society, Sacramento, California, Feb. 8, 1960; the Pacific Coast Society of Orthodontists, Palo Alto, California, Feb. 23, 1960; the Washington, D. C., Dental Study Club, Washington, D. C., Bethesda Naval Hospital, March 12, 1960; the Northeastern Society of Orthodontists, New York, New York, March 13, 1960; the Pedodontists Society of California, Carmel, California, April 4, 1960; the California State Dental Association, San Francisco, California, April 26, 1960; the California Speech and Hearing Association, Southern Section, and Orange County Society of Crippled Children and Adults, Inc., Newport Beach, California, May 21, 1960; the Fresno Dental Health Council, Fresno, California, Oct. 1, 1960; the Medical Evangelist College, Loma Linda, California, Feb. 15, 1961; St. Louis University Alumni meeting, March 6 and 7, 1961.

called open-bite cases, in which the bite is opened from the first or second molar on one side to the same tooth on the opposite side. In these cases the mandible appears to be literally bent by the position of the tongue between the teeth. This either affects the mandible at gonion, displaces the head of the

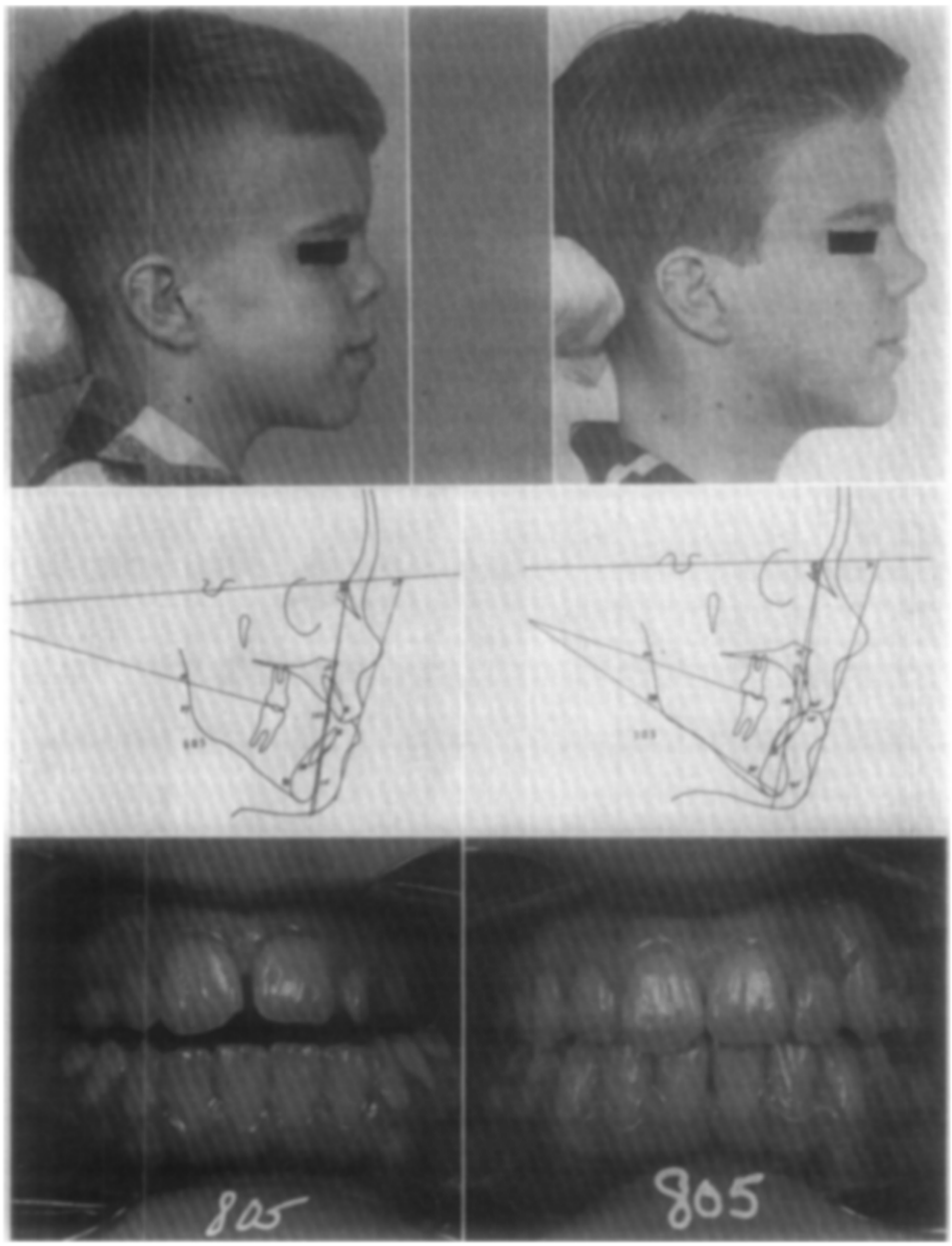

Fig. 1. Patient J. S. Photographs and cephalometric tracings before and after treatment. Note complete open-bite and mandibular plane angle of 37 degrees before treatment.

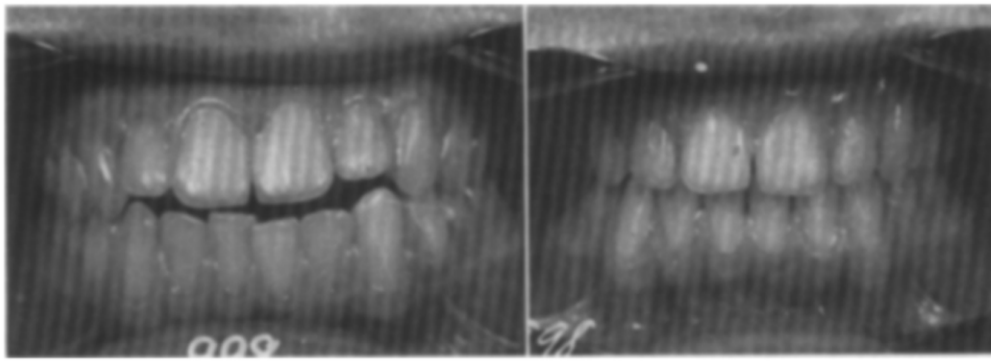

A.

B.

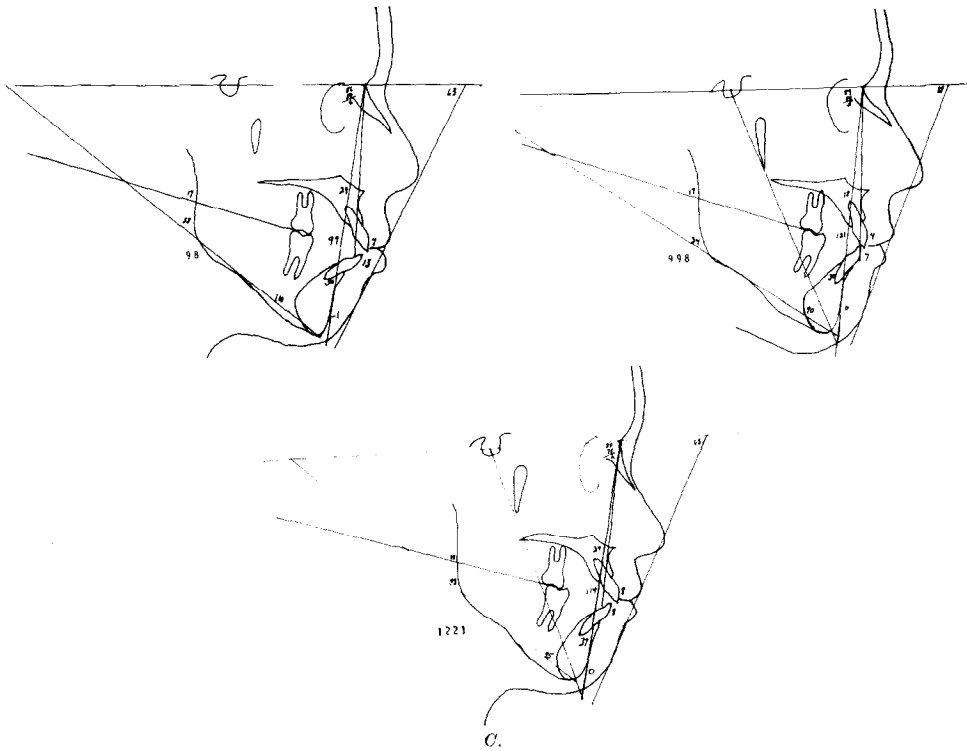

C.

Fig. 2. *A* and *B*, Patient R. M. Intraoral photographs and cephalometric tracings before and after habit training and orthodontic treatment. Note open-bite and mandibular plane angle of 38 degrees before treatment. *C*, Sister of Patient R. M., with same tongue habit. Note same anterior tooth position and same bony pattern.

condyle, or affects the length of the ramus or rami. With the tongue held between the teeth and the added pressure of the muscles of deglutition against it, we may assume that mandibular growth may be altered and that this causes some of our steepest mandibular plane angles. These are the changes seen in

many cases of open-bite and bimaxillary protrusion in which the teeth are pushed forward by constant tongue action.

The photographs and cephalometric tracings shown in Figs. 1 to 5 illustrate what constant pressure can do to the shape of the mandible, the alveolus, the dental structure, and the position of the anterior and posterior teeth as well as the changes that take place as a result of habit correction and orthodontic treatment.

The abnormal swallowing habit is definitely one of the causes of some of our severe Class III malocclusions. For many years I have hesitated to go on record as implicating the abnormal swallowing habit in the etiology of Class III

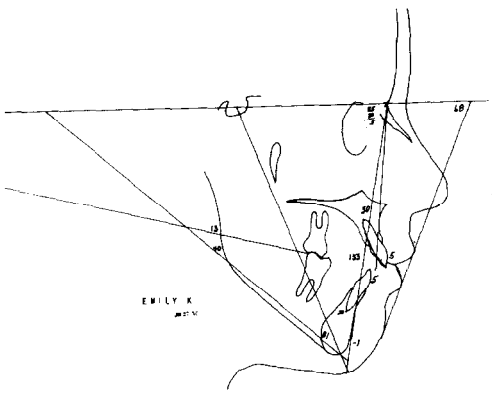

Fig. 3.

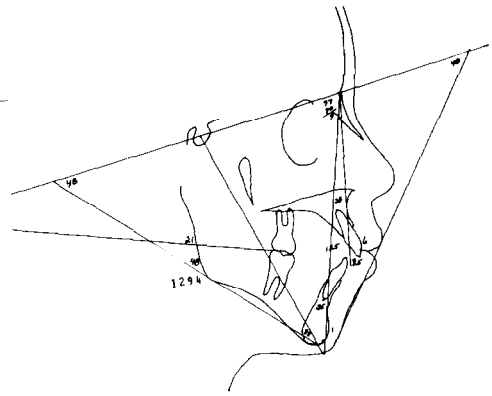

Fig. 4.

Fig. 3. Patient E. K. Cephalometric tracing showing open-bite and steep mandibular plane angle of 40 degrees.

Fig. 4. Patient B. P. Cephalometric tracing showing mandibular plane angle of 48 degrees.

malocclusion. However, an understanding of the mechanics involved in abnormal swallowing and the observation of complete collapse of the buccal and anterior segments in cases of complete cross-bite with blocked-out upper canines and lateral incisors have made the relationship between abnormal swallowing and Class III malocclusion apparent to many others who have followed this problem closely. Orthodontists in the Phoenix and Tucson areas who have studied the causes of this malocclusion believe that there is a definite correlation between abnormal swallowing and Class III malocclusion. Abnormal swallowing causes a complete collapse of the maxilla, and adverse growth of the mandible is caused by the masticating pressure of a complete cross-bite on the upper jaw. Many a child who has never learned to swallow properly has never put his tongue against his palate; as a result, the palate is so narrow that it is mechanically impossible to place the tongue against it. Also, in Class III malocclusion the tongue is usually enlarged as a result of the position in which it is placed in abnormal swallowing.

Fig. 6 shows another example of a severe Class III malocclusion with the typical short ramus and a steep mandibular plane angle. This patient placed the tongue on the occlusal surfaces of all the lower teeth and then closed the teeth against it. The irritation caused by this abnormal use actually widened the

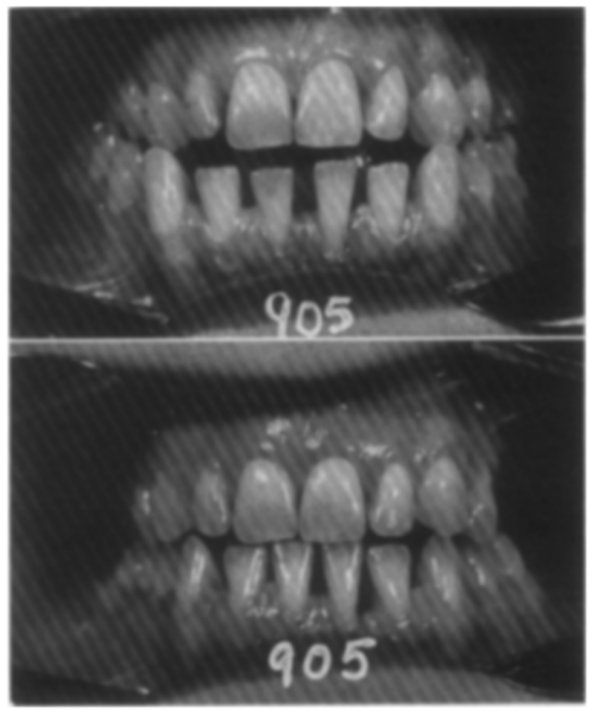

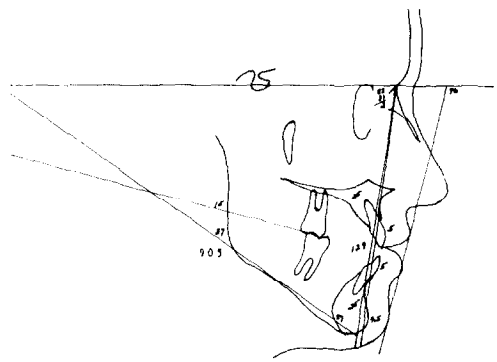

Fig. 5. Patient A. S., aged 33 years. Note complete open-bite and mandibular plane angle of 37 degrees.

Fig. 6. *A* and *B*, Patient G. N. Mandibular plane angle of 40 degrees before treatment and 45 degrees after treatment. Class III malocclusion with steep mandibular plane angle of 45 degrees is due in part to abnormal swallowing habit. Note change in position of anterior teeth after treatment. Note also, in before-treatment intraoral photograph, that upper maxilla is in complete cross-bite, with upper right canine blocked out, upper left lateral incisor in contact with premolar, and upper left canine impacted and high over lateral incisor. *C*, Another example of a Class III malocclusion caused by abnormal swallowing.

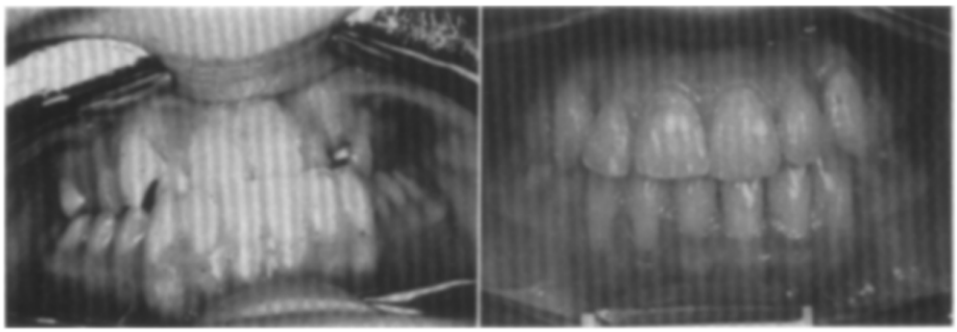

A.

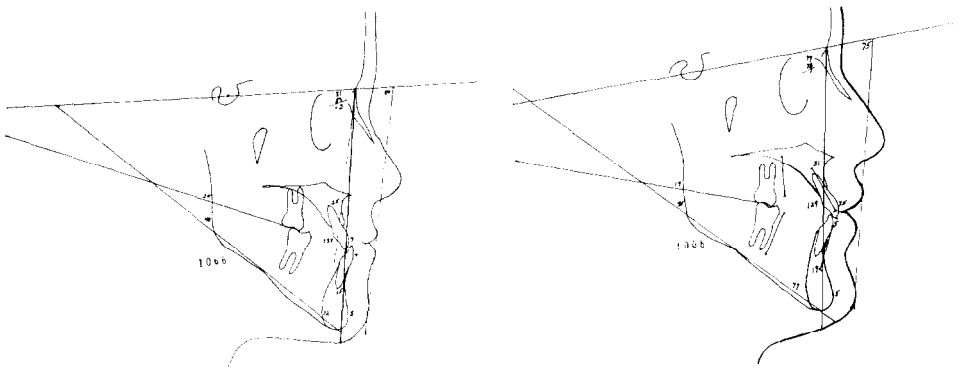

B.

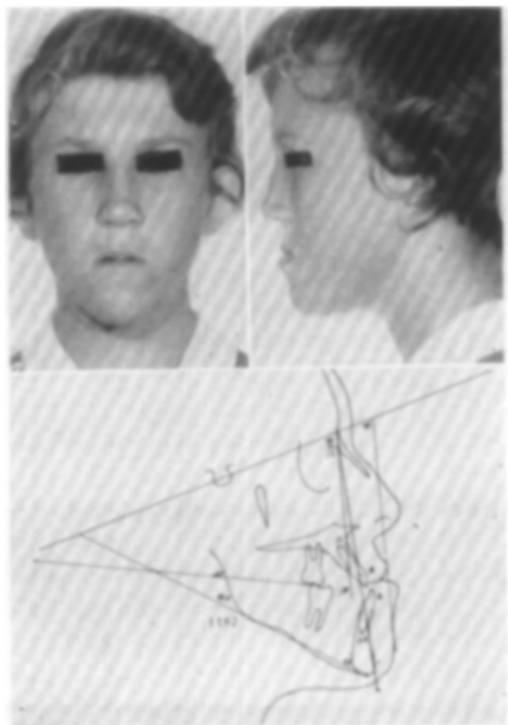

C.

Fig. 6. *(For legend, see opposite page.)*

tongue and made it larger. Upon completion of habit therapy and correction of the total cross-bite and the Class III malocclusion, the tongue returned to a more nearly normal size and it was possible for the patient to place the tongue properly against the palate between the confines of the teeth in normal deglutition.

As I have previously pointed out,[1] the old-fashioned nipple, such as the one shown in Fig. 7, is the principal cause of abnormal swallowing. This nipple is so long that it reaches almost to the back of the throat, making it impossible for the infant to put the tongue against the roof of the mouth, even if he wanted to. To make matters worse, the mother usually places extra holes in the end of the nipple to make sure that the milk will flow freely. This, in itself, changes the mechanics of swallowing. To keep from drowning, the infant very quickly learns to suck and to swallow with the tip of the tongue between the gum pads and with the tongue troughed to receive the flow of milk. This tongue action also takes place in infants whose mothers have so much milk that the slightest pressure on the breast causes the milk to flow. To date, after a period of seventeen years, I have seen eight breast-fed children whose mothers told of having had a tremendous amount of milk which would flow freely without any sucking on the child's part. These children had the same problem as the child subjected to improper bottle feeding.

In 1960 I described a nipple that will help to eliminate this problem.[1] It is possible to spoil any nipple by punching several holes in it to allow milk to flow too freely, thus causing the child to become an abnormal swallower.

It is strange how difficult it is to get a child started on a feeding program. Some children have a very strong sucking urge at birth and, much to my surprise, some have a complete sucking urge. I have had one patient whose sucking urge was completely absent, so that the child had to be fed with an eye dropper. I mentioned this during a panel discussion before a group of speech therapists, and the pediatrician on the panel informed me that he has seen several children who were born without the sucking urge. Thus, nipples should vary, as far as the flow of milk is concerned. In order for a newborn infant to get his full supply of milk without tiring before he finishes his formula, two holes probably should be placed in the nipple. Later, when the sucking urge is stronger, the nipple should be replaced by one that has only one hole in it, thus making it necessary for the child to suck harder. I suspect that the use of such nipples would eliminate many of our abnormal swallowing problems and, with them, many of our orthodontic problems.

It is surprising how difficult it is to teach others to adopt proper nursing methods, once other customs have been well established. At our local hospital I supplied nipples of this type to the nursery and to the physicians in charge. Much to our surprise, the first thing the nurses did was to place many holes in the nipples to facilitate the easy flow of milk, thus defeating the purpose of the nipples. In other words, the nipples were now the same type as those used before except for the shape, which did simulate the shape of the breast.

The pacifier seems to be coming back into vogue. There is a great difference between sucking the thumb, the fingers, or some foreign object and sucking a

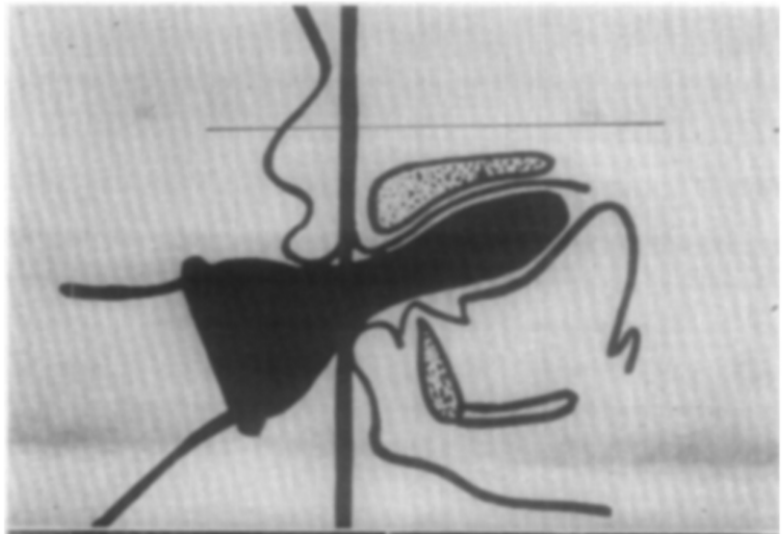

Fig. 7.

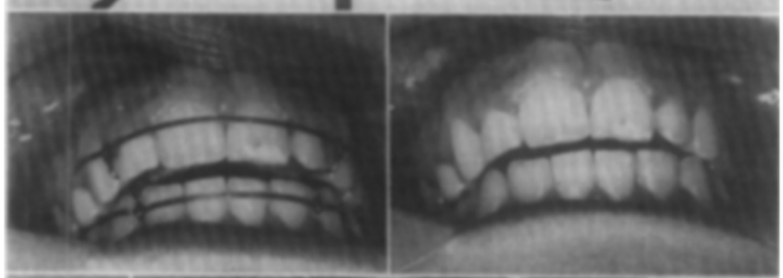

Fig. 8.

Fig. 9.

Fig. 7. Old-fashioned nipple which is principal cause of abnormal swallowing. Note great length of this nipple, which reaches almost to back of child's throat.

Fig. 8. Patient S. S. This patient has an abnormal swallowing habit and a tongue-thrust. *Left*, With retainer; *right*, without retainer.

Fig. 9. Patient W. T. Treatment was discontinued because of patient's failure to cooperate. Note position of tongue.

pacifier which more nearly resembles the human breast in contour. As we all know, Nature places an infant's mouth and mandible in a very retruded position at birth in order that he may nurse properly at the breast. Unlike the thumb or fingers, the pacifier has a flat object in front with which the infant can form a seal with his lips. He has to thrust his jaw forward in order to suck properly on the pacifier, and in many cases this will help to develop the mandible.

Fig. 8 shows the dentition of a girl who had an abnormal swallowing habit and a tongue-thrust. This patient was treated solely by orthodontic methods; no habit control was used. As the photographs show, there is a tendency toward an open-bite, and the upper teeth are still slightly protruded to accommodate the tongue. It is difficult to treat such cases to the normal anterior closure, and relapse usually occurs if they are treated to the normal incisal closure.

Fig. 9 shows a case in which treatment was discontinued because of the patient's failure to cooperate in practicing her habit lessons. The orthodontist is advised not to treat such cases unless the patients will make the effort to learn to swallow properly.

It is important to note that although tongue-thrust does protrude the upper anterior teeth, there are many cases (for example, those involving open-bite) in which the tongue in retraction has a tendency to pull the lower anterior teeth

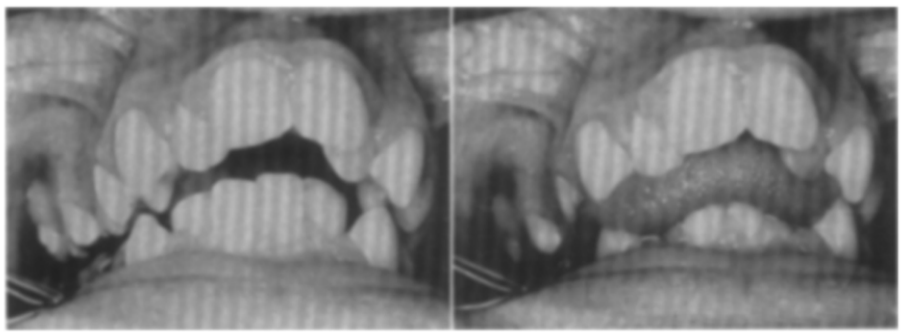

Fig. 10. Tongue pulling lower incisors lingually at completion of the swallowing act.

lingually into a collapsed and retruded position (Fig. 10). As Strang has pointed out, "A denture in malocclusion is in complete muscular balance."

Failure to correct inherent muscular activity is one of the most important causes of orthodontic failure. *These could well be called our functional malocclusions.*

In order to bring some semblance of order to the chaotic descriptions of patients with abnormal swallowing habits, we have attempted to classify these cases in four distinct groups.

Group 1.—In most cases of the first group there is a diastema between the upper central incisors. Figs. 11, 12, and 13 show shining examples of cases in which tongue-thrust has affected the anterior segment. The tongue action may be a little bit different in these cases, and there are many variations of the tongue in these classifications.

Group 2.—In the second group of cases a nonocclusion or open-bite is seen not only between the anterior teeth but in the posterior teeth as well—usually from the first molar forward or, if the second molars are in place, from the second molar forward. Formerly, these were considered the most difficult cases to treat. However, with the advent of habit therapy and correction of the abnormal swallowing habit, these cases respond faster than most cases in which

patients have normal swallowing patterns and severe malocclusions. First of all, once the habit is removed and the pressure no longer exists, it is easier to close a complete open-bite with the aid of vertical elastics and a chin strap. We do not know whether we are actually depressing the posterior molars, extruding the anterior teeth, doing both, or changing the shape of the mandible. Only a series of headfilms from about fifty cases will show whether we are (1) changing the mandible, repositioning the head of the condyle, or thinning the meniscus, (2) depressing the molars, or (3) changing the mandibular angle at gonion and actually bending the mandible. It seems sensible to believe that the main body of the mandible and alveolus can be changed by orthodontic means when this headgear is used. In my office the results obtained in open-bite cases that were once considered untreatable tend to bear this out. Some of these cases show a complete open-bite, often from the second molar forward. In many cases the

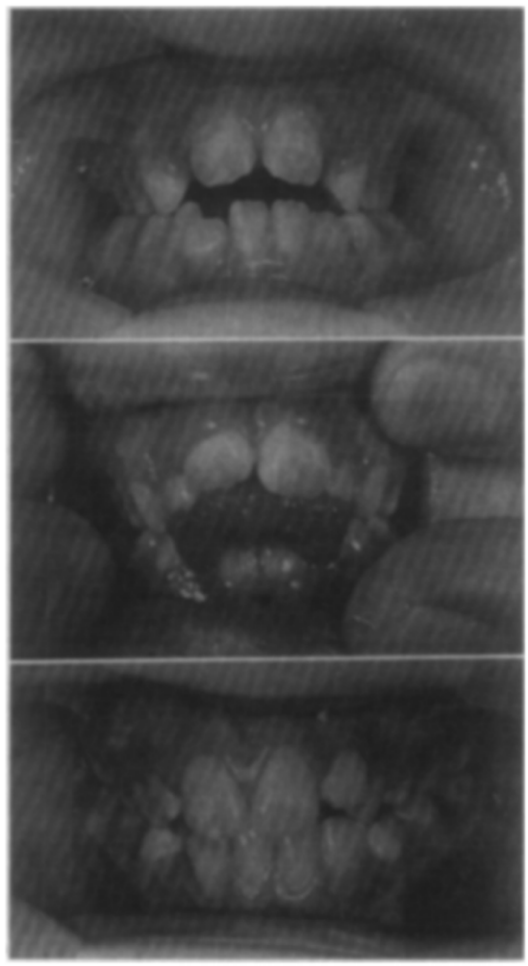

A.

B.

C.

Fig. 11. Patient P. L. Note diastema between upper central incisors as result of tongue-thrust. *A*, Before treatment. *B*, Tongue in place. *C*, At conclusion of habit therapy and first period of orthodontic treatment.

Fig. 12.

Fig. 13.

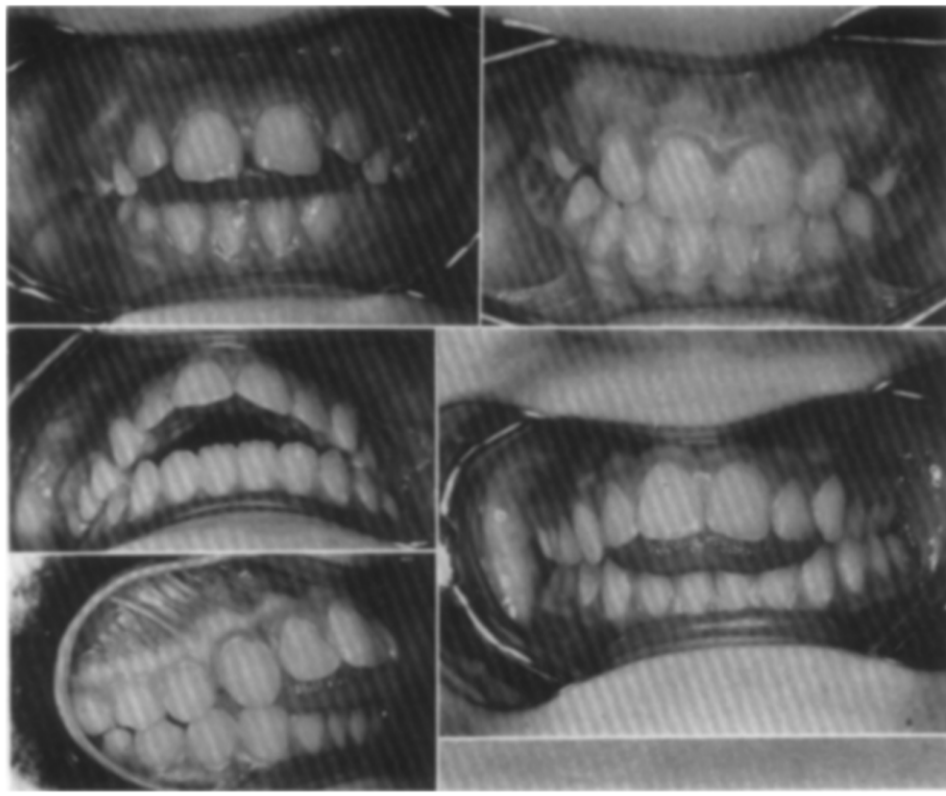

Fig. 12. Patient D. V. Intraoral photographs before and after treatment and wearing of an upper working retainer.

Fig. 13. Patient M. B. Photographs illustrating effects of tongue-thrust.

child not only thrusts the tongue between the teeth but also puts it on the occlusal surface of the teeth and closes the teeth against it. After being thus bitten for several years, the tongue becomes quite large.

Fig. 1 shows a good example of this type of case. The patient has a mandibular plane angle of 34 degrees with practically a complete cross-bite and open-bite from first molar to first molar. Figs. 14 to 17 also illustrate this phenomenon. Patient D. M. (Fig. 17) received orthodontic therapy with a complete banding technique and then had a complete relapse. This case shows exactly what happens when the bands and retainers are removed and no provision is made for correction of the abnormal swallowing habit.

In the case of Patient J. N. the bite has been closed in the posterior region. Fig. 18 shows the method used in closing this patient's bite. All orthodontists are familiar with these cases in which relapse occurs faster than in other orthodontic cases. Such cases have been problems to the general dentist for many, many years. In the past the dentist ground off the occlusal surfaces of the upper and lower posterior teeth, closing the bite sometimes as much as ¼ inch; six months later, as a result of the tongue habit, this bite would be open

Fig. 14.

Fig. 15.

Fig. 16.

Fig. 14. Patient T. S. Tongue appears very large after patient has spent years biting it.

Fig. 15. Patient S. G. Note practically complete cross-bite and open-bite from first molar to first molar.

Fig. 16. Patient K. R. Another case in which cross-bite and open-bite have been caused by abnormal swallowing habit.

the same as before. These open-bite cases have been the downfall of many prosthodontists because they did not recognize the open-bite position of the teeth before extraction and, when the dentures were made, placed the teeth in good occlusion. Many have found that these patients, in attempting to swallow, have dislodged their upper denture. When dental prostheses are made for patients who have passed the age of 60, it is wise to create a space for the tongue so that the patients may continue to swallow abnormally. I know a dentist who prevailed upon a 65-year-old patient to let him improve her bridge, which

another dentist had constructed with the teeth in an open-bite relation. The old bridge was removed and the incisor area was closed, leaving no room for the patient's tongue. Much to the dentist's surprise, the patient was uncomfortable and could not swallow and eat. Within three or four weeks, it became necessary to remove the bridge and remake it to allow the patient to swallow abnormally.

Fig. 17.

Fig. 18.

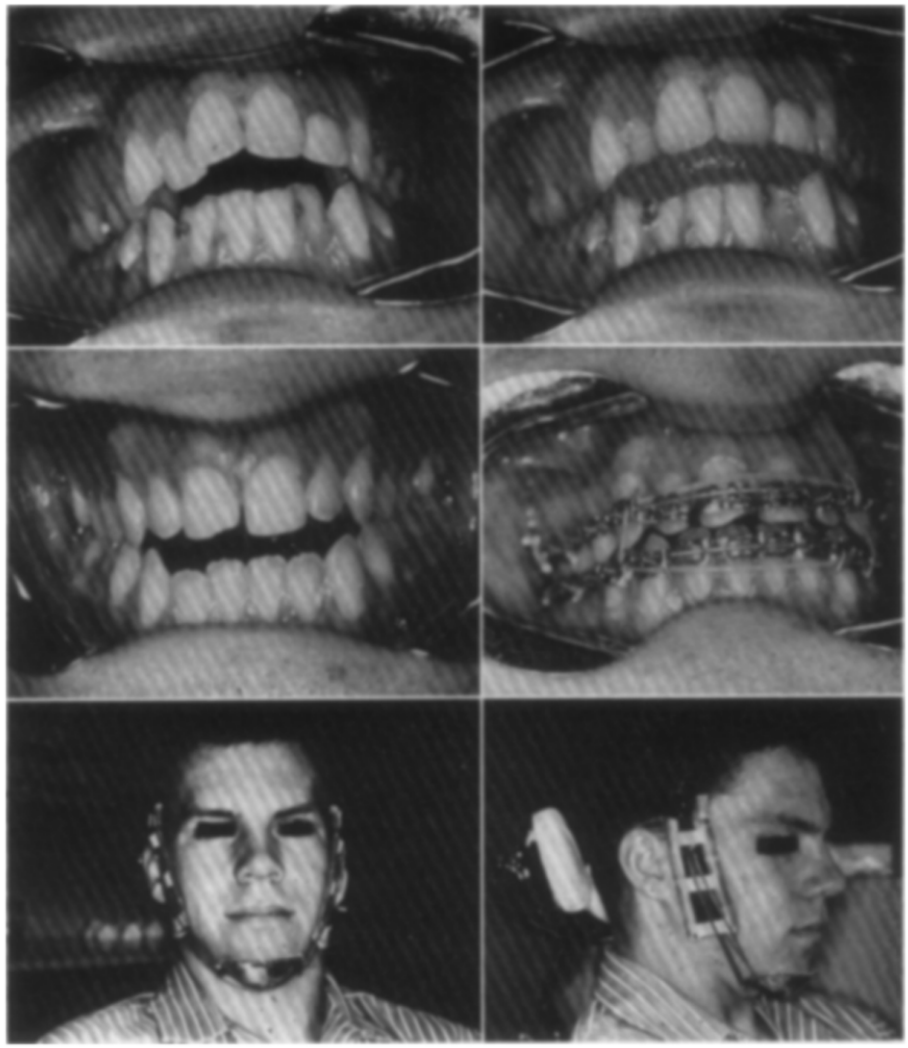

Fig. 17. Patient D. M. Complete relapse followed orthodontic treatment when no provision was made for correction of abnormal swallowing habit.

Fig. 18. Patient J. N. Photographs showing method used to close bite.

In the case of Patient A. S. (Fig. 5, *A*), an open-bite practically destroyed the occlusion and created a traumatic occlusion. The patient was referred to a periodontist, who was requested to treat the soft tissues and to see if the teeth

could be saved. The periodontist felt helpless, as he recognized the abnormal swallowing habit, and referred the patient to my office for habit therapy. Although this patient was 33 years of age, the habit was corrected and a full band hook-up was placed on her teeth to give her a fair occlusion at this age. The lower anterior teeth were very loose and had to be held while the bands were made. At the completion of treatment and following removal of the periodontally involved posterior teeth, this patient was able to masticate her food properly and to keep her remaining teeth in good condition.

Group 3.—The third type of abnormal swallowing is the side-thrust. In these cases a nonocclusion in the premolar and canine area has been created by the lateral displacement of the tongue. These so-called side-thrust cases are the most difficult to correct, and usually there is a recurrence of this type of swallowing in our completed open-bite cases. In our complete open-bite cases we may see a tendency for the bite to open slightly in the premolar area on either one or both sides. Examples of the conditions created by this side-thrust are shown in Figs. 19 to 22.

Group 4.—The fourth type of abnormal swallowing is seen in the so-called close-bite case. These cases are also more difficult to correct and are the most difficult to detect. In many of these cases the swallowing habit goes unsuspected until orthodontic treatment has been completed, and then the orthodontist is confused to find that the patient has an open-bite. He feels that the abnormal swallowing habit has been developed during treatment, which is not true. It takes a great deal of training before the operator can detect this type of abnormal swallowing, as the habit is easily disguised. The patient, although he has a severe close-bite, opens his mouth sufficiently (in extreme cases almost as much as an inch) to accommodate the tongue between the teeth when he swallows abnormally. Close-bite cases are shown in Figs. 23 to 26.

The case of Patient P. P. is of particular interest. The central incisors were unexposed and impacted and had to be exposed surgically so that bands could be placed on them. When this child closed his mouth, the lower anterior teeth hit on the palate; even in this condition, when the patient swallowed, he opened his mouth wide enough to enable him to place the tongue between the teeth.

This last group of cases is the reason we feel that the placing of any mechanical contrivance (such as a hayrake or a jig) in the mouth to keep the tongue from coming forward will end in failure. First of all, these children have a natural fence with their teeth closed. If they would keep the teeth closed tightly, in centric occlusion, they could not force the tongue between the anterior teeth and would not disturb the dentition. This is not the case, however, for these children open the mouth and swallow with the tongue between the teeth, and they do the same with an artificial appliance. Fig. 27 shows an intraoral photograph of Patient P. P. after completion of habit therapy and orthodontic treatment.

It is not easy to explain why abnormal swallowing affects some children. In some cases we feel that the tongue habit is not so severe; otherwise, it would have opened the bite the same as in the complete open-bite cases.

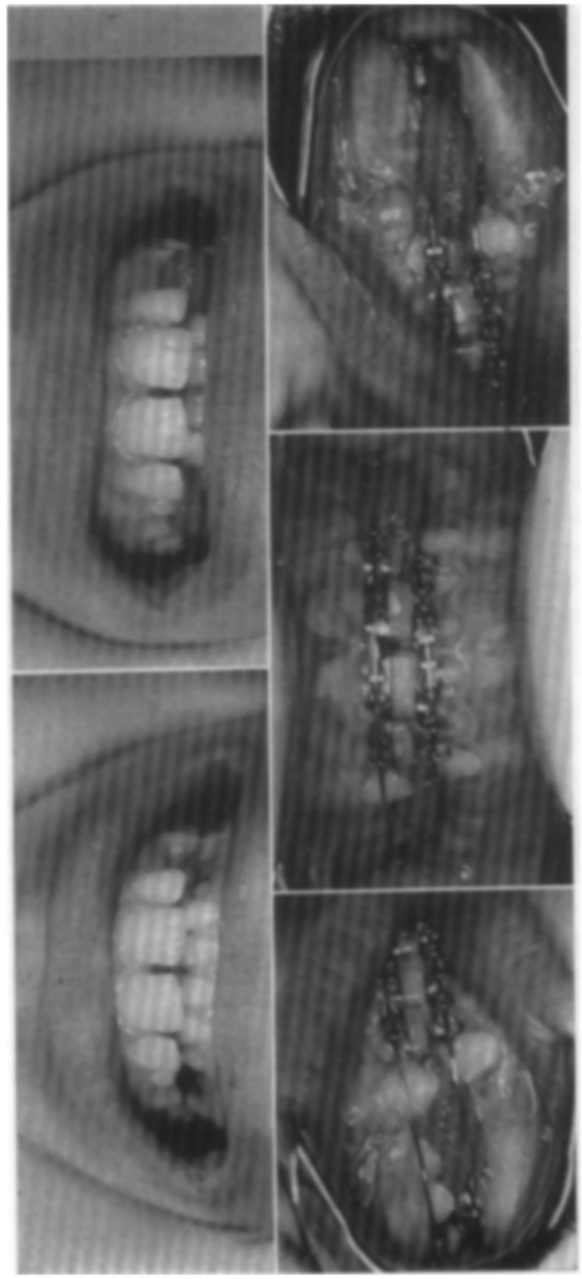

Fig. 19.

Fig. 20.

Fig. 19. Patient D. L. D. Nonocclusion in premolar and canine area thrust habit.

Fig. 20. Patient D. O. Malocclusion caused by lateral displacement of tongue in abnormal swallowing.

Fig. 21.

Fig. 22.

Fig. 23

Fig. 21. Patient R. Y. Another case in which side-thrust habit has resulted in open-bite in premolar and cuspid area.

Fig. 22. Patient E. D. Note malocclusion caused by side-thrust swallowing habit.

Fig. 23. Patient L. G. Note close-bite caused by abnormal swallowing habit.

Also, the tongue habit is countered by a leaning habit. The head constitutes, roughly speaking, one-fifth of the body weight; thus, if the child weighs 100 pounds, the head weighs about 20 pounds. Leaning on the chin, then, as many children do while studying and watching television, will have a tendency to depress the posterior teeth and cause the so-called close-bite in spite of the tongue habit. In orthodontic treatment we use very light pressure compared to the 20 pounds of pressure exerted by the child in leaning on the chin. Hence, one can readily see that in many of the cases in which orthodontic treatment has placed the teeth in a correct incisal edge relationship, the bite will be closed

Fig. 24.

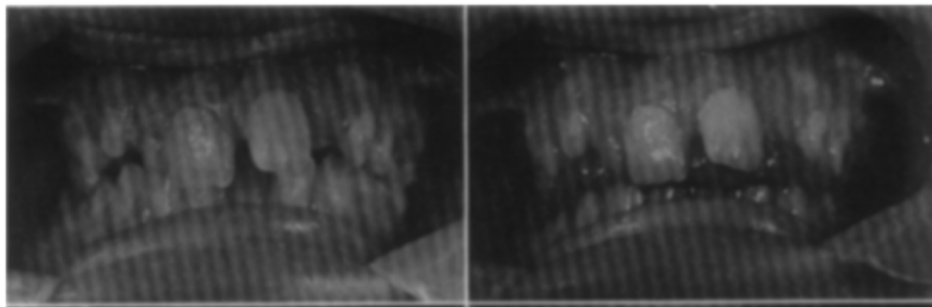

Fig. 25.

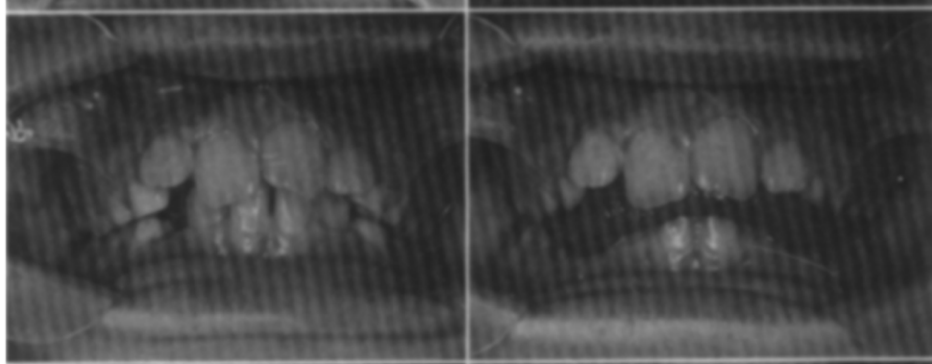

Fig. 26.

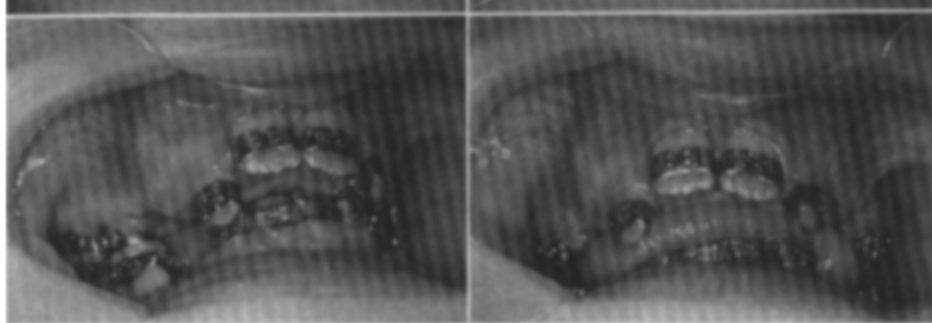

Fig. 27.

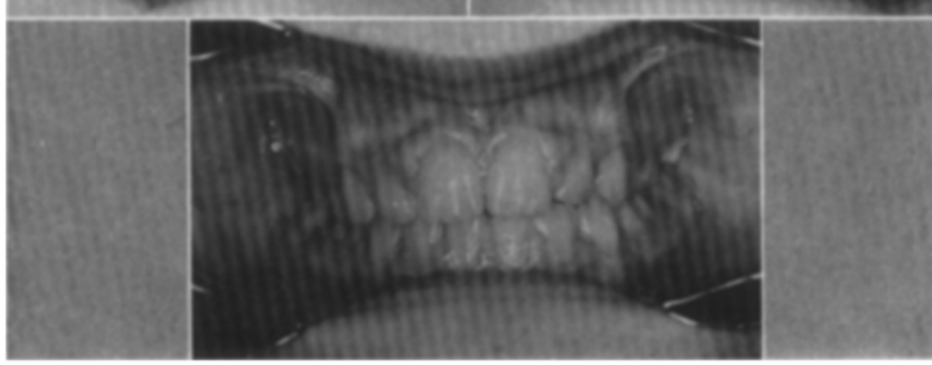

Fig. 24. Patient D. C. Note close-bite produced by holding tongue between anterior teeth while swallowing.

Fig. 25. Patient T. P. Another case in which abnormal swallowing is present in a close-bite.

Fig. 26. Patient P. P. Unexposed impacted central incisors had to be exposed surgically so that bands could be placed on them.

Fig. 27. Patient P. P. Intraoral photograph following habit therapy and orthodontic treatment.

after several years of chin leaning. This supposition seems justified in these close-bite cases; therefore, I do not believe that a mechanical contrivance will work.

I think it is well to show a failure in a case that I treated some twenty years ago (Fig. 28). The cross-bite was corrected, as indicated in the before- and after-treatment photographs. The bite was closed, but even during retention it

Fig. 28. Patient A. S. before and after treatment of cross-bite caused by abnormal swallowing.

opened up in the anterior region. Nothing was done to correct the facial deformity caused by abnormal use of the orbicularis and mentalis muscles. The pencil mark on the lower anterior teeth shows the position in which the upper incisor edges were placed over the lower anterior teeth at the completion of treatment. Some years later when this patient was married, her mouth was in the position seen today, with an open-bite. This is one of the reasons that we started to think about some method to correct the abnormal swallowing habit in order to have our orthodontic treatment results remain stable.

Dr. Robert Gawley has come forth with a mechanical aid (Fig. 29) that may work when it is not possible to give therapy to correct an abnormal swallowing habit; I think this is one of the best mechanical means that I have seen to date. I sometimes recommend that this be used in extreme side-thrust cases. The latex rubbers are placed on the side and the patients are instructed, in the words of Dr. Gawley, that "when the tongue touches the elastic they are to realize that these elastics are supposedly charged with electricity and it will give them a shock, and every time that their tongue touches the elastic it is to remind them that their tongue is in an improper position." I think that this, with habit therapy for correction of side-thrust, will help to correct these cases faster. Figs. 30 and 31 show some cases in which the bite closed after correction with habit therapy alone. (In the case of Patient M. Y., shown in Fig. 31, a central incisor was fractured during the habit lessons.) Cases that remained stable after habit correction and orthodontic therapy are shown in Figs. 1, 2, and 12.

Fig. 29.

Fig. 30.

Fig. 31.

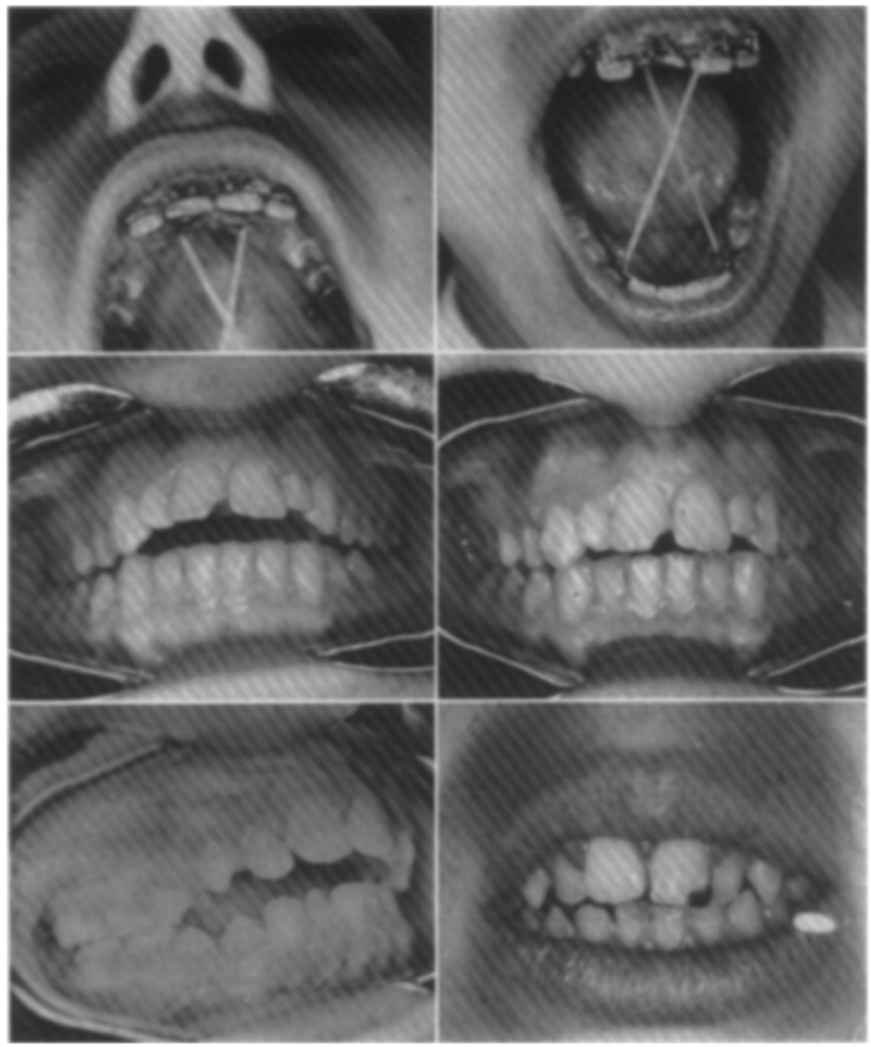

Fig. 29. Mechanical aid developed by Robert Gawley for use in correction of bad swallowing habits.

Fig. 30. Patient L. C. Photographs before and after habit therapy which resulted in closure of bite.

Fig. 31. Patient M. Y. Habit therapy alone brought about correction of this patient's malocclusion.

Other mechanical appliances are used by some orthodontists, and some of them will be shown here. Patient S. S. had worn the crib shown in Fig. 32, *B* on the upper lingual appliance to keep her tongue from coming forward. I do not recommend the use of such a crib, as it prevents the child from putting the tongue in the proper position in swallowing. I also do not believe in the use of cribs for correction of thumb-sucking, for the crib covers the palate and keeps

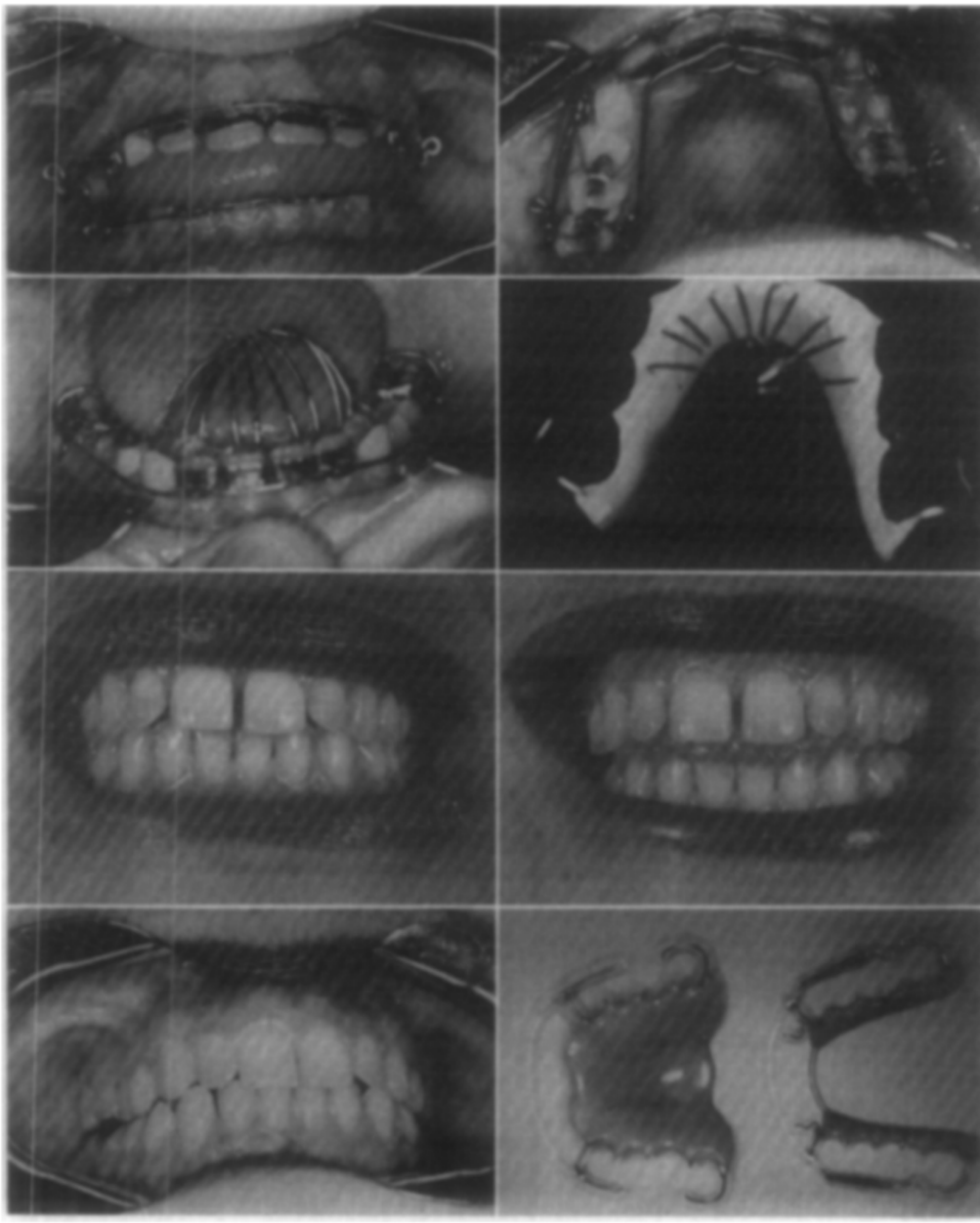

Fig. 32.

Fig. 3:

Fig. 32. Patient S. S. Photographs showing crib used to prevent tongue from going between teeth at night.

Fig. 33. Photographs before and after closure of spaces between anterior teeth in 42-year-old woman.

the tongue from being in its normal place for proper swallowing. In my office all mechanical appliances are removed from the child's mouth to allow the child to have a normal positioning of the tongue with correct habit therapy. For night swallowing the crib shown in Fig. 32, *C* and *D* was placed on the lower teeth. The crib was in the form of a partial plate with wires coming up over the tongue to keep it from going between the teeth. You can imagine how happy this child was when these mechanical gadgets were removed after six months

Fig. 34. Patient K. L. Note bimaxillary protrusion produced by abnormal swallowing habit in which both upper and lower teeth were pushed forward by tongue during deglutition.

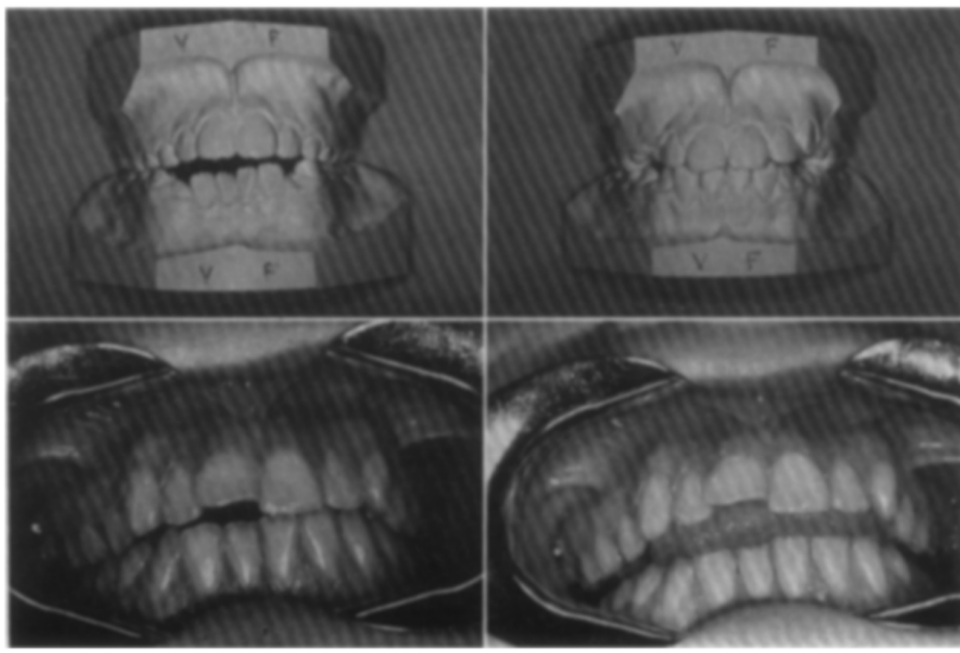

Fig. 35. Patient V. F. Tongue habit caused relapse of malocclusion which had been successfully treated in mixed dentition.

and habit therapy was instituted in its place! Rarely do mechanical gadgets or cribs correct a problem involving the twenty muscles used in normal deglutition. The proper muscles have to be retrained to swallow correctly, and I have seldom seen this done successfully by mechanical means alone.

Dentists are also interested in these abnormal swallowing habits because of the tendency for teeth to migrate later in life. Fig. 33 shows the case of Mrs. H. who, at the age of 42 years, was pushing all the anterior teeth forward because of an abnormal swallowing habit. Spacing was created between the upper and lower six anterior teeth; this progressive pushing of the teeth in the anterior position opened up the contacts in the posterior teeth, causing the formation of pockets and periodontal disturbances. These patients usually request their dentists to replace an inlay or an amalgam filling to restore or keep the teeth in contact so that food will be prevented from going between the teeth, and this is exactly what happened in this particular case. The patient was referred to me for habit training. The habit was corrected and all the spaces were closed with a removable appliance, as shown in Fig. 33.

The case of Patient K. L. shows exactly what happens when a severe abnormal swallowing habit forces the whole facial profile into a complete bimaxillary protrusion (Fig. 34). Both the upper and lower teeth were pushed forward by the tongue until there was a complete forward displacement of tooth and bone.

Figs. 17 and 35 show cases that were treated beautifully by some of our finest orthodontists, only to relapse as a result of the tongue habit. If habit therapy is instituted in these cases, the orthodontist will find that the result of orthodontic treatment is more stable. Also, the patient's facial appearance is greatly improved, since the orbicularis is at complete rest in normal deglutition and the mentalis muscle is not used to shove the lower lip into a forward and upward position.

When the child has two habits, such as thumb-sucking and abnormal swallowing, the thumb-sucking habit should be corrected first. The lessons and methods used to correct the abnormal swallowing habit and thumb-sucking will be explained in a forthcoming article.

My appreciation to my associate, Dr. R. B. Croft, for the cephalometric drawings used in this article.

REFERENCE

1. Straub, Walter J.: Malfunction of the Tongue. Part I, AM. J. ORTHODONTICS 46: 404-424, 1960.

No. 2, El Cerrito.